



CASE REPORT

Schwannoma masquerading as a thyroid nodule: A diagnostic delimita.

Pashmal Yousaf¹, Ushna Talat², Hafiz Muhammad Sufyan³, Haroon Javaid Majid⁴

Article Citation: Yousaf P, Talat U, Sufyan HM, Majid HJ. Schwannoma masquerading as a thyroid nodule: A diagnostic delimita. Professional Med J 2024; 31(07):1125-1128. <https://doi.org/10.29309/TPMJ/2024.31.07.8220>

ABSTRACT... We present a case of a 70 years old female presenting with a long-standing neck swelling with a recent increase in size and new onset pain. It was initially diagnosed and operated on as a cold nodule of thyroid as her thyroid scan showed left cold nodule and FNAC was inconclusive. However, a final diagnosis of schwannoma with Antoni A structures was made on histopathological attributes. Schwannomas are benign peripheral nerve tumors which grow slowly on parent nerves. The mainstay of treatment is surgical excision. To avoid unnecessary or inappropriate interventions, thorough pre-operative assessment is required in case of thyroid or non-thyroidal lesions as most are hypoechogenic on ultrasonography and fine needle aspiration has low diagnostic yield. The key pre-operative investigations are ultrasound and ultrasound guided cytology and immunohistochemical staining (for example S-100, calcitonin, CEA, thyroglobulin, TTF-1, melan-A, HMB45 and Ki-67). MRI is also a good diagnostic tool in neck swellings where diagnosis is uncertain.

Key words: Head and Neck Neoplasms, Neck Swelling, Schwannoma.

INTRODUCTION

Schwannomas also known as neurilemmas or neuromas are benign proliferation of Schwann cells which form myelin in peripheral nerve sheath. They usually arise sporadically or in association with type 2 neurofibromatosis. They do not contain axons but may cause pain if the affected nerve is displaced. In contrast, neurofibromas are also benign peripheral nerve tumors, but the proliferation involves all nerve elements. These also arise sporadically and are generally associated with type 1 neurofibromatosis.

Schwannomas are common in 3rd to 6th decade of life, presenting a mass lesion with point tenderness. Continuous pain or pain at the site of a previously non tender swelling may suggest malignant transformation which is rare. They are known for their eccentric location over peripheral nerves, most commonly seen in the upper limbs as well as the head and neck region.¹

Head and neck schwannomas may mimic a thyroid swelling if they present as cervical or intra-

thyroidal (rarely) lesions.² As these swellings can be mistaken as thyroid nodules, pre-operative diagnosis can be challenging. Here we present such a rare case of intra-thyroid schwannoma which was operated on as a cold nodule of thyroid and later histology report revealed a cellular schwannoma.

CASE REPORT

A 70 years old female, with no known co-morbidities and insignificant past medical, surgical and family history presented with a six years history of swelling in the front of her neck. It was small, round and there was no associated pain or difficulty in swallowing or breathing.

For the last six months, she started feeling pain in the swelling, gradual in onset, sharp in character, of moderate severity, exaggerated by food intake and relieved by rest (of voice and of swallowing). She managed the pain with over-the-counter analgesics available and sought medical help with outdoor patient department check-up at our facility.

1. MBBS, Trainee Registrar General Surgery and Surgical Oncology, Shaikh Zayed Hospital, Lahore.
2. MBBS, Internee General Surgery and Surgical Oncology, Shaikh Zayed Hospital, Lahore.
3. MBBS, Trainee Registrar General Surgery and Surgical Oncology, Shaikh Zayed Hospital, Lahore.
4. MBBS, FRCS (Ed), Professor and Head General Surgery and Surgical Oncology, Shaikh Zayed Hospital, Lahore.

Correspondence Address:
Dr. Pashmal Yousaf
Department of General Surgery and Surgical
Oncology
Shaikh Zayed Hospital, Lahore.
pashmal.yousaf@gmail.com

Article received on: 04/04/2024
Accepted for publication: 10/06/2024

On examination, a 2 by 3 cm round, non-tender, firm swelling in left lobe of thyroid, which moved with deglutition and not with protruding of tongue, with regular margins, not adherent to overlying skin and with no regional lymphadenopathy or any neurological deficit.

She was advised work-up for the swelling.

Her thyroid function tests were ordered (27/01/2023) which were normal; free T4 0.65 ng/dL, TSH 2.68 mIU/mL and free T3 2.60 pg/mL (reference range; fT4 0.61-1.12 ng/dL, TSH 0.4-4.0 mIU/mL, fT3 2.5-3.9 pg/mL respectively).

Ultrasound neck (06/03/2023) showed a hypoechoic, asymmetrically enlarged left lobe of thyroid with a 6.5 by 6.2 cm nodule having increased vascularity. Right lobe of thyroid and isthmus are normal in size, echotexture and vascularity.

Thyroid scan (08/03/2023) showed a nodule in left thyroid lobe extending up to the isthmus and superiorly to below the mandible, shows reduced radiotracer uptake. Right lobe shows fairly homogenous radiotracer uptake. Complimentary SPECT-CT of the neck shows a large (6.6 x 6.3 cm) heterogenous density, mildly hypoechoic nodular lesion in the left lobe corresponding to the palpable nodule, causing tracheal shift to the right. A diagnosis of cold nodule of left lobe of thyroid was made.

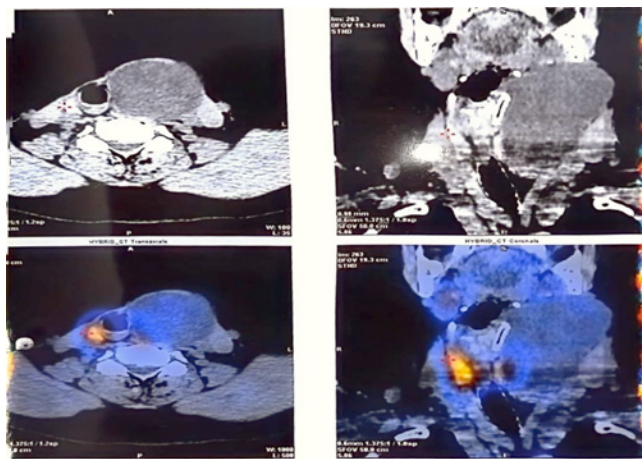


Figure-1. Thyroid scan showing left cold nodule

She underwent fine needle aspiration for cytology

(FNAC) which was inconclusive. CT scan of neck (14/04/2023) reported left lobe of thyroid is enlarged and shows a large circumscribed heterogeneously enhancing soft tissue mass measuring 10.4x7.1x6.7 cm in craniocaudal, transverse and anteroposterior dimensions. No internal calcifications seen. Trachea is displaced towards rightwards however no narrowing is seen. Left sided strap muscles are compressed and displaced by this large mass. Left carotid artery and internal jugular vein are displaced laterally however no intraluminal filling defect seen. No retrosternal extension seen. No erosion of thyroid cartilage seen. Few enlarged cervical lymph nodes are seen in bilateral level II and III of cervical chain largest seen on left at level II measuring about 9x7.5mm and largest on the right measures about 10x6.5mm. The oral floor muscles are symmetrical. The spaces of oral cavity are clear. Salivary glands show no abnormality. Pharynx and larynx show normal boundaries and wall thickness. Cervical vessels show normal appearance. An impression of large left thyroid mass lesion was made.

She was optimized pre-operatively and underwent left lobectomy on 16th May 2023. Intra-operative findings were of an 8 by 8 cm round thyroid swelling, rest of the thyroid gland is found to be normal. Bilateral recurrent laryngeal nerves and parathyroid glands identifies and saved.

The post-operative histopathology report (18/05/2023) diagnosed the specimen as benign spindle cell lesion consistent with schwannoma. Gross examination findings were a 10x8x6 cm left lobectomy specimen, serial sectioning revealed grey white homogenous cut surface.

Microscopic description revealed benign nerve sheath lesion composed of areas revealing hypercellular oval to spindle cells containing spindle to wavy palisading nuclei with inconspicuous cytoplasm and hypocellular areas revealing similar spindly cells scattered against loose myxoid background. Focal areas reveal verocay bodies. No mitosis and necrosis are seen. The intervening stroma reveals thick-walled blood vessels.

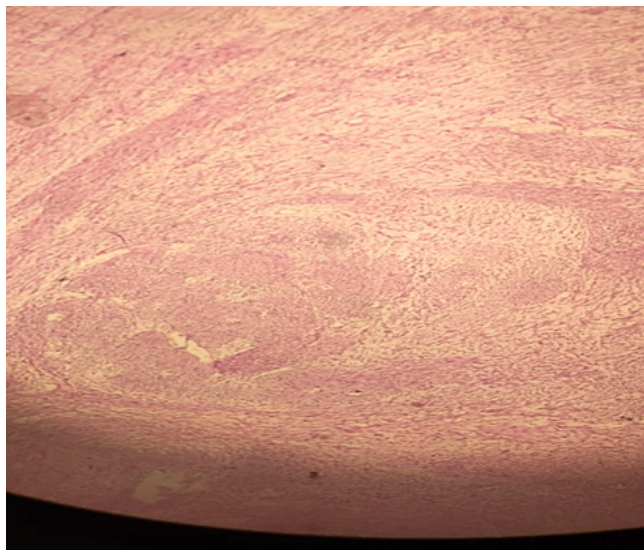


Figure-2. Microscopic picture showing schwannoma composed of a haphazard arrangement of bland cells with spindled and oval nuclei.

Patient experienced an uneventful post-operative period. Her post-operative calcium and albumin levels were chased over a course of two weeks for any possible hypocalcemia. She remained normo-calcemic and hence was not put on any calcium supplements. On her discharge, she was advised to follow up in any nuclear medicine, oncology and radiotherapy institute. She was also cleared from oncological point of view as there was no need for any further treatment (surgical or oncological). Patients remains on our follow up presently.

DISCUSSION

Intra-thyroidal schwannomas are reported from all over the world in the age group 30 to 60 years. The first case report of a thyroid schwannoma was reported in 1964 by Delany and Fry.³ Like in our case report, most of the authors have reported thyroid schwannomas with inconclusive fine needle aspiration cytology reports. As post-operative histology report revealed a schwannoma for us, we regretted not having performed a pre-operative MRI or immunohistochemical staining as done by Sravanthi et al.⁴ in case report published in 2017. This is true for cases which on FNAC show spindle type cells (schwannoma) or for cases which are inconclusive on FNAC, an MRI performed will confirm pre-operative diagnosis

and hence further management.

Pre-operative diagnosis of schwannoma is often a challenge as FNA findings are inconclusive. In a case series of 30 patients who were diagnosed with head and neck schwannoma, FNAC was only 20% diagnostic.⁵ Our patient was also in the same line.

The mainstay of treatment for a schwannoma is surgical excision. Due to their encapsulated nature and eccentric nature, these tumors can be excised completely without damaging the parent nerve. In cases where the tumor is entwined with nerves, subtotal resection and observation is the approach. No further adjuvant therapy is normally required. As in our case, per-operative findings revealed an encapsulated mass and therefore a lobectomy was performed as a cold nodule of left lobe of thyroid was the diagnosis at that time. After reviewing the histopathology report, no further management was necessary as resection is curative for schwannomas. Our current patient was advised biannual follow up as she had undergone successful resection.

When evaluating an enlarging, nodular thyroid swelling, pathologies of origins other than thyroid for example nerve cells must also be considered and further investigations must be done accordingly to rule them out. Imaging in form of initial ultrasounds and later MRI can be utilized when non-thyroidal tumors are suspected. Fine needle aspiration cytology and immunohistochemistry are also valuable modalities.

CONFLICT OF INTEREST

The authors declare no conflict of interest.

SOURCE OF FUNDING




This research received no specific grant from any funding agency in the public, commercial, or not-for-profit sectors.

Copyright© 10 June, 2024.

REFERENCES

1. Helbing DL, Schulz A, Morrison H. **Pathomechanisms in schwannoma development and progression.** Oncogene. 2020 Aug 6; 39(32):5421-9.
2. Mohammad A, Iqbal MA, Wadhwan A. **Schwannomas of the head and neck region: A report of two cases with a narrative review of the literature.** Cancer Research, Statistics, and Treatment. 2020 Jul 1; 3(3):517-25.
3. Delaney WE, Fry KE. **Neurilemoma of the thyroid gland.** Annals of Surgery. 1964 Dec; 160(6):1014.
4. Nagavalli S, Yehuda M, McPhaul LW, Gianoukakis AG. **A cervical schwannoma masquerading as a thyroid nodule.** European Thyroid Journal. 2017 Jul 1; 6(4):216-20.
5. Liu HL, Yu SY, Li GK, Wei WI. **Extracranial head and neck schwannomas: A study of the nerve of origin.** European Archives of Oto-Rhino-Laryngology. 2011 Sep; 268:1343-7.

AUTHORSHIP AND CONTRIBUTION DECLARATION

No.	Author(s) Full Name	Contribution to the paper	Author(s) Signature
1	Pashmal Yousaf	Manuscript writing.	
2	Ushna Talat	Data collection,	
3	Hafiz Muhammad Sufyan	Operating surgeon, Manuscript writing.	
4	Haroon Javaid Majid	Proof reading.	