



ORIGINAL ARTICLE

## A prospective study of outcome of CT-Scan-Guided stereotactic biopsy for brain pathology.

Aurangzeb Kalhoro<sup>1</sup>, Kashif Ahmed<sup>2</sup>, Pervaiz Ali<sup>3</sup>, Abdul Sattar M. Hashim<sup>4</sup>

**Article Citation:** Kalhoro A, Ahmed K, Ali P, Hashim AM. A prospective study of outcome of CT-Scan-Guided stereotactic biopsy for brain pathology. Professional Med J 2024; 31(06):982-987. <https://doi.org/10.29309/TPMJ/2024.31.06.8000>

**ABSTRACT... Objective:** To assess the effectiveness of stereotactic biopsy in individuals with brain lesions and describe the surgical procedure utilized during this to analyze the features of pathologies linked to the application of this surgical approach. **Study Design:** Descriptive study. **Setting:** Neurospinal Cancer Care Institute in Karachi. **Period:** January 2019 and June 2022. **Methods:** This study had approval from the ethics committee and patients provided written informed permission Under general anaesthesia the biopsy was performed. The definitive diagnosis based on histopathological report were considered positive. **Results:** We had of 61 patients, gender wise males were 37 (55.73%) and females were 24(39.34%), with calculated mean age was 41.01years (range between 15–67 years). Majority of patients were between the age of 33 and 66 years (67.21%). Pre and post procedure, patients had to go brain MRI brain or CT scan brain for helping in localization. The lesion was supratentorial as observed in 56 patients (91.80%) and 5(8.19%) were infratentorial. The post contrast enhancements were observed in 35 patients (57.37%). **Conclusion:** The study presented compelling evidence supporting the ease and accuracy of the stereotactic procedure in targeting the lesion, Stereotactic intervention for lesions has been shown to be both effective and safe.

**Key words:** Brain Lesions, CRW Frame, Omayya Reservoir, Stereotactic Biopsy.

### INTRODUCTION

Stereotactic biopsy is the minimal invasive method for getting the brain tissue sample for subsequent diagnosis and management. With 70 years and more in field of neurosurgery, the stereotactic biopsy has advanced with every moment at present the accuracy of stereotactic biopsy can be >90%.<sup>1</sup> The precise histopathological diagnosis is essential in contemporary oncological management for patient can affect overall survival rate and prognosis specially in deep lesions.<sup>2</sup> Frequently, utilizing open surgery to confirm the histology of intraaxial lesions situated above the tentorium may unnecessarily increase the risk of postoperative complications.<sup>3</sup> The chance of impacting eloquent parenchymal regions is a concern, particularly when combining histological verification with radical surgery in patients. Contemporary neurosurgical approaches prioritize the potential benefits of

minimally invasive procedures.<sup>4</sup>

In suspected cases along with biopsy the magnetic resonance (MR) spectroscopy, and such tools can be used to provide a reliable molecular diagnosis.<sup>5</sup> The complications vary from 0.7 to 4%, morbidity ranges from 3 to 13%. Complication can be seizures, hemorrhage, neurological impairment and loss of consciousness. Symptomatic hemorrhage range varies from 0.9 to 8.6%, whereas considering asymptomatic bleeding, the range may be up to 59.8%.<sup>6</sup> Frameless surgery with good accurate results and robotic surgery are advances in the field of brain stereotactic biopsy.<sup>7</sup>

The study aims to assess the effectiveness of Fiducial-Based biopsy in individuals with brain lesions and its diagnostic accuracy.

1. FCPS, FACS, MBA, FICS, CHPE, Consultant Neurosurgeon, Neuro Spinal & Cancer Care Institute, Karachi.  
2. MBBS, FCPS (Neurosurgery), Consultant Neurosurgeon, Neuro Spinal & Cancer Care Institute, Karachi.  
3. MBBS, FCPS (Anesthesia), Consultant Anesthesiologist, Neurospinal Cancer Care Institute  
4. Ph.D, M.D (Neuro Surgery), Ex Prof JPMC, Medical Director, Neuro Spinal & Cancer Care Institute

**Correspondence Address:**

Dr. Aurangzeb Kalhoro  
Flat No. A2, Chappal Beach,  
Luxury Appartment, Clifton Block-4, Karachi.  
[draurangzebkalhoro@gmail.com](mailto:draurangzebkalhoro@gmail.com)

**Article received on:** 16/11/2023  
**Accepted for publication:** 15/02/2024

**METHODS**

We conducted a descriptive study at the Neurospinal Cancer Care post graduate Institute in Karachi, involving 61 patients between January 2019 and June 2022. This study had approval from the ethics Board of Neurospinal cancer care institute with IRB 1566/2020 and patients provided written informed permission after understanding pros and cons the procedure, under general anaesthesia the procedure of biopsy was performed, using the Leksell frame protocol for lesions in the supratentorial and some infratentorial regions. The definitive diagnosis based on histopathological report were considered positive.

The inclusion criteria encompassed the following conditions lesions located in deep critical areas of the brain, that can be the basal ganglia system, sensory cortex, can be area of motor cortex, invasive lesions or distinguished neurological signs symptoms, brain stem lesion or midline region; lesions ill observed on MRI scans brain or CT scan brain, cystic deep lesions, insertion of an Ommaya reservoir while exclusion criteria include individuals who are suspected of having vascular pathology, patients with shift of midline that may need surgical decompression, obstructed brain cisterns, in addition patients with coagulation disorders, low Glasgow coma score that is less than 8 score, children aged below 2 years.

Biopsies targeting cortical, thalamic, or posterior fossa lesions prone to vascular bleeding were performed under general anaesthesia using the Cosman-Roberts-Wells (CRW) stereotactic frame. The frame was securely fixed, and coordinates were determined with a CT or MRI scan.

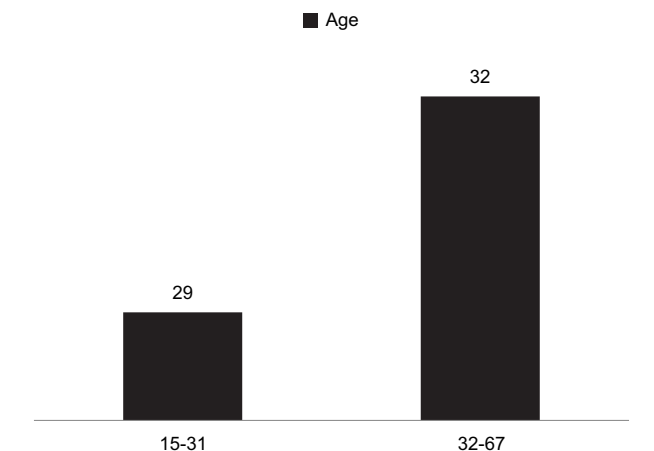
Post-imaging, patients were placed supine on the Operation Theatre table, secured in a Mayfield head holder, with an entry point 3cm lateral to the midline and 2.5cm anterior to the coronal suture. For brain stem lesions, a perpendicular coronal plane to the head ring was established. The parietal lobe direction was chosen to avoid the ventricles, determining optimal lateral placement for the burr hole. Coordinates (X, Y, and Z) were

pre-determined from the CT scan.

The biopsy needle’s distance was measured, and a precise biopsy was conducted, including aspiration of any identified cyst or abscess. Post-procedure, patients were observed for one day.

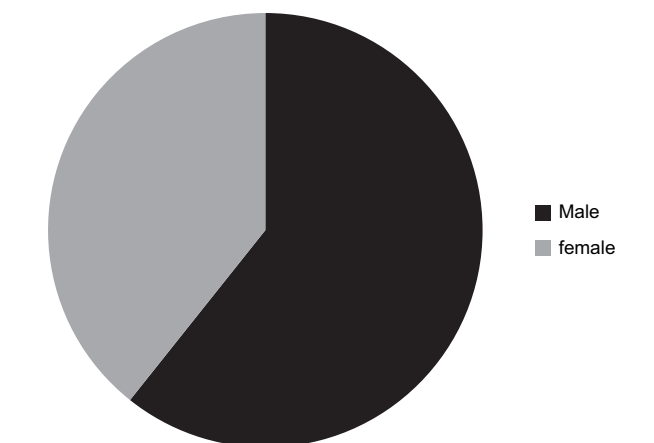
**RESULTS**

Total number of 61 patients was included in study. 52.5% has age category of 32-67 years. (See Figure-1) The age of the patients is significantly related to the outcome of patient with P-value (0.0001).



**Figure-1. Age P-value (0.0001)**

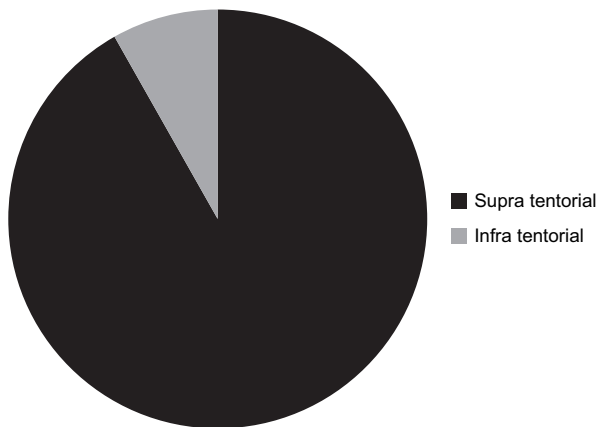
Regarding Gender; 60.7 % were male (Figure-2)



**Figure-2. Gender**

Pre and post procedure, patient had to go for MRI brain contrast or CT scan brain contrast for assisting brain localization of lesion, the post contrast enhancement were observed in 57.37%.

Regarding the location of the lesion; 91.8% of lesions were supra-tentorial in location. (Figure-3)



**Figure-3. Location of lesion**

The method was also utilized for placement Ommaya reservoir in brain, hematoma evacuation, site of lesion was approached through nearest and safest trajectories for the stereotactic procedures depended, as mention in Table-I. Regarding the entry point for stereotactic surgery; Most of the entry points were made through right peri-coronal regions (32.8%) after that right parietal (29.5%). If the data is weighted against the outcome that is hospital stay, it shows insignificance with p value 0.305. (Table-I)

Entry Point	Number (%)	P-Value
Right parietal	18 (29.5%)	0.305
Left parietal	9 (14.8%)	
Right peri-coronal	20 (32.8%)	
Left peri-coronal	11 (18.0%)	
Right occipital	2 (3.3%)	
Left occipital	1 (1.6%)	

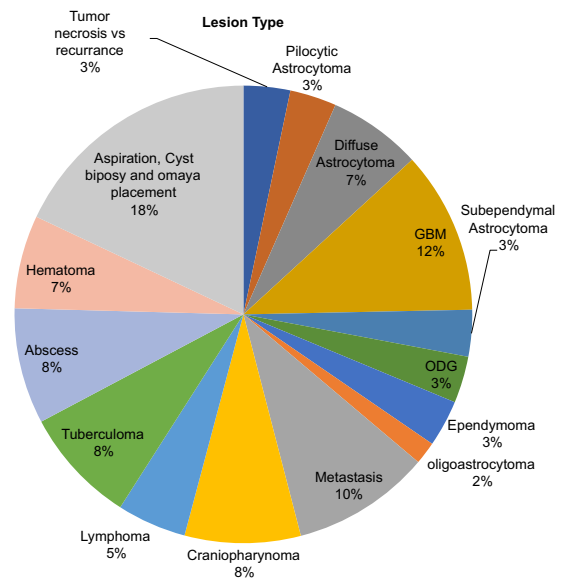
**Table-I. Entry point for stereotactic surgery**

Regarding the Side of the lesions that was made through Stereotactic surgery; most of the lesions were deep (52.5%). The data if compared with the number of hospital stay, it shows borderline level of significance p-value 0.045. (Table-II)

Site	Number (%)	P- Value
Deep	32 (52.5%)	0.045
Deep and eloquent	9 (14.8%)	
Deep and Small	11 (18.0%)	
Eloquent	9 (14.8%)	

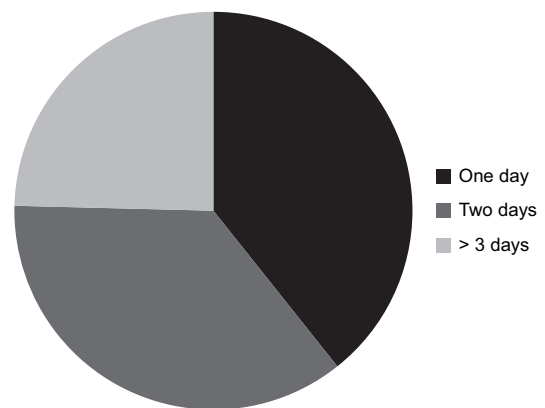
**Table-II. Site of the lesion**

Among 61 cases stereotactic guided procedures, 47 were biopsies (77%) while 14(22.95%) were done for cystic aspiration and hematoma evacuation. The demographic representation of histopathological diagnosis is presented in Figure-4. The other procedures were Ommaya Reservoir insertion, abscess aspiration, hematoma aspiration, and cyst aspiration.



**Figure-4. P-value 0.005**

The lesion type is significantly related to the outcome of the patients (P-value 0.005) Regarding the stay of hospital that is our major outcome and number of complications illustrated below. (Figure-5) Most patients were discharge on first day (39.3%) and followed by 2<sup>nd</sup> day discharge 36.1%.

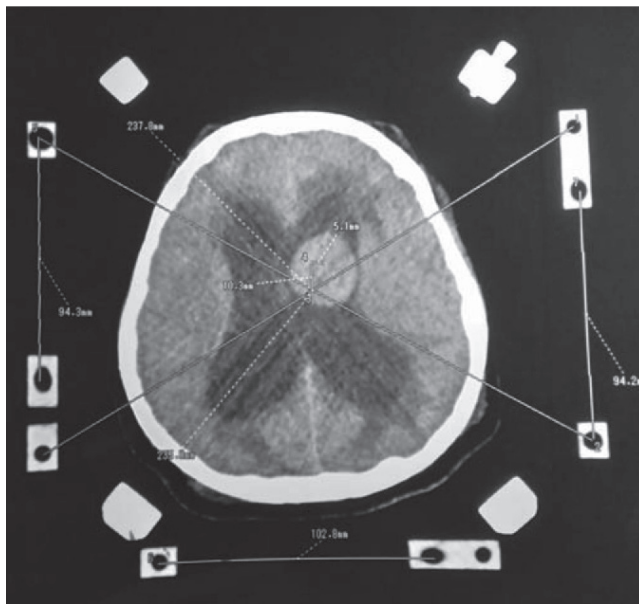


**Figure-5. Hospital stay**

The post operative CT scan had shown minimized cranial hemorrhage in two patients and neurological deficit in one patient had fail biopsy in one which was re done as shown in Table-III.

Complication	Number
Failed biopsy	1 (1.6%)
Minimal hemorrhage	2 (3.3%)
Neurological Deficit	1 (1.6%)
No complications	57 (93.4%)

**Table-III. Post-Operative complication (P-value; 0.145)**



**Image-1. The CT scan Brain showing the biopsy planning**

## DISCUSSION

In our study, we achieved successful evacuation of three intracerebral hematomas, with significant improvements observed in all patients with hematomas located in the thalamic area and frontoparietal region. As part of the treatment, aspiration and cyst wall biopsy, as well as Ommaya reservoir insertion, were performed in 11% of the patients. Additionally, brain abscesses were present in 9.8% of the patients and were successfully evacuated. Regarding tumors, glioblastoma and metastasis were the most commonly observed types. In cases where biopsy attempts failed, alternative procedures were performed to diagnose the tumors accurately. The occurrence of neurological deficits was relatively low, affecting approximately 1.63% of the patients. Overall, our study demonstrates the efficacy and highlights the importance of timely interventions

for intracerebral hematomas, brain abscesses, and tumors to achieve positive patient outcomes.

Histological diagnosis is crucial in treating intracranial lesions. Until now, frame-based stereotactic surgery has been the primary approach for minimized invasive biopsy. Nevertheless, with advancements in computer systems and neuronavigation technology, modern neurosurgical practice is favoring neuronavigated (frameless) stereotaxy. Research indicates promising results in terms of efficacy, safety, and diagnostic value. However, there remains a scarcity of literature on this minimally invasive technique and its diagnostic yield.<sup>8,9</sup>

Fluorescein-assisted stereotactic brain method biopsies taken can demonstrate a high likelihood in recent advances, the Robotic -assisted stereotactic biopsy is safe and feasible. With such advancements, future platforms are more powerful.<sup>10</sup>

In the past even the biopsy of brain stem was not possible but in recent years the biopsy of brain stem can be with minimal side effects with a high diagnostic rate and low morbidity.<sup>11,12</sup>

The success of obtaining positive brain biopsy was 95.2% in the following study, with the complication rate of 3.6%. stereotactic brain biopsy was considered safe method in diagnosing lesions specially deeply located lesions.<sup>13</sup>

The transcerebellar biopsy done in semi-sitting position is effective method for obtaining a diagnostic tissue sample in brainstem lesions. We have noted that adoption of the technical modifications described in this article has aided in improving the safety and ease of the procedure.<sup>14</sup>

## CONCLUSION

The study presented compelling evidence supporting the ease and accuracy of the stereotactic procedure in targeting the lesion, Stereotactic intervention for lesions has been shown to be both effective and safe, offering high diagnostic value, may help to sparing patients from major surgical interventions and the relevant

complications from stereotactic procedure are comparatively less frequent, resulting in less morbidity and mortality.

### CONFLICT OF INTEREST

The authors declare no conflict of interest.

### SOURCE OF FUNDING




This research received no specific grant from any funding agency in the public, commercial, or not-for-profit sectors.

Copyright© 15 Feb, 2024.

### REFERENCES

- Lara-Almunia M, Hernandez-Vicente J. **Symptomatic intracranial hemorrhages and frame-based stereotactic brain biopsy.** *Surgical Neurology International.* 2020; 11. doi 10.25259/SNI\_102\_2020
- Qin F, Huang Z, Dong Q, Xu X, Lu T, Chen J, et al. **Stereotactic biopsy for lesions in brainstem and deep brain: A single-center experience of 72 cases.** *Brazilian Journal of Medical and Biological Research.* 2021 Jul 23; 54:e11335. <https://doi.org/10.1590/1414-431X2021e11335>
- Hervey-Jumper SL, Berger MS. **Maximizing safe resection of low-and high-grade glioma.** *Journal of Neuro-oncology.* 2016 Nov; 130:269-82. <https://doi.org/10.1007/s11060-016-2110-4>
- Mladenovsk M, Valkov I, Ovcharov M, Vasilev N, Duhlenki I. **High grade glioma surgery-clinical aspects and prognosis.** *Folia Medica.* 2021 Feb 28; 63(1):35-41. DOI: 10.3897/folmed.63.e55255
- Akshulakov SK, Kerimbayev TT, Biryuchkov MY, Urunbayev YA, Farhadi DS, Byvaltsev VA. **Current trends for improving safety of stereotactic brain biopsies: Advanced optical methods for vessel avoidance and tumor detection.** *Frontiers in Oncology.* 2019 Oct 2; 9:947. <https://doi.org/10.3389/fonc.2019.00947>
- Riche M, Amelot A, Peyre M, Capelle L, Carpentier A, Mathon B. **Complications after frame-based stereotactic brain biopsy: A systematic review.** *Neurosurgical Review.* 2021 Feb; 44:301-7. <https://doi.org/10.1007/s10143-019-01234-w>
- Terrier L, Gilard V, Marguet F, Fontanilles M, Derrey S. **Stereotactic brain biopsy: evaluation of robot-assisted procedure in 60 patients.** *Acta Neurochirurgica.* 2019 Mar 13; 161:545-52. <https://doi.org/10.1007/s00701-019-03808-5>
- Kesserwan MA, Shakil H, Lannon M, McGinn R, Banfield L, Nath S, et al. **Frame-based versus frameless stereotactic brain biopsies: A systematic review and meta-analysis.** *Surgical Neurology International.* 2021; 12. DOI 10.25259/SNI\_824\_2020
- Nevzati E, Chatain GP, Hoffman J, Kleinschmidt-DeMasters BK, Lillehei KO, Ormond DR. **Reliability of fluorescein-assisted stereotactic brain biopsies in predicting conclusive tissue diagnosis.** *Acta Neurochirurgica.* 2020 Aug; 162:1941-7. <https://doi.org/10.1007/s00701-020-04318-5>
- Dawes W, Marcus HJ, Tisdall M, Aquilina K. **Robot-assisted stereotactic brainstem biopsy in children: Prospective cohort study.** *Journal of Robotic Surgery.* 2019 Aug 1; 13:575-9. <https://doi.org/10.1007/s11701-018-0899-x>
- Hirano Y, Shinya Y, Aono T, Hasegawa H, Kawashima M, Shin M, et al. **The role of stereotactic frame-based biopsy for brainstem tumors in the era of molecular-based diagnosis and treatment decisions.** *Current Oncology.* 2022 Jun 28; 29(7):4558-65. <https://doi.org/10.3390/curroncol29070360>
- Akay A, İşlekel S. **MRI-guided frame-based stereotactic brainstem biopsy procedure: A single-center experience.** *Neurocirugía (English Edition).* 2019 Jul 1; 30(4):167-72. <https://doi.org/10.1016/j.neucie.2019.03.001>
- Akay A, Rüksen M, İşlekel S. **Magnetic resonance imaging-guided stereotactic biopsy: A review of 83 cases with outcomes.** *Asian Journal of Neurosurgery.* 2019 Mar; 14(01):90-5. DOI: 10.4103/ajns.AJNS\_81\_17
- Ramnadh RK, Vamsi KY, Yerragunta T, Arvind KV, Shah V. **Stereotactic brainstem biopsy: Technical aspects with emphasis on role of awake craniotomy.** *Indian Journal of Neurosurgery.* 2020 Mar 27; 9(02):080-4. DOI: 10.1055/s-0039-3402623

**AUTHORSHIP AND CONTRIBUTION DECLARATION**

No.	Author(s) Full Name	Contribution to the paper	Author(s) Signature
1	Aurangzeb Kalhoro	Conceptualization of project, Statistical analysis.	
2	Kashif Ahmed	Drafting, Revisions, Statistical analysis.	
3	Pervaiz Ali	Data collection, Conceptualization of project, Statistical analysis, Data collection.	
4	Abdul Sattar M. Hashim	Drafting, Revision.	