



CASE REPORT

## Pulmonary alveolar microlithiasis: A case report.

Muhammad Waseem<sup>1</sup>, Ahmed Uzair<sup>2</sup>, Nauman Ijaz Bhatti<sup>3</sup>, Muhammad Sajawal<sup>4</sup>, Amna Abid<sup>5</sup>

**Article Citation:** Waseem M, Uzair A, Bhatti NI, Sajawal M, Abid A. Pulmonary alveolar microlithiasis: A case report. Professional Med J 2024; 31(02):322-325. <https://doi.org/10.29309/TPMJ/2024.31.02.7937>

**ABSTRACT...** An uncommon autosomal recessive condition called pulmonary alveolar microlithiasis (PAM) is characterized by the buildup of intra-alveolar calcifications inside the lung parenchyma. In this case report, a 16-year-old female patient with PAM is examined in-depth clinically and radiologically. The patient's radiographs revealed dense consolidation in both lungs. The diagnosis of PAM was confirmed by high-resolution computed tomography (HRCT), which showed bilateral, extensive and symmetrical distribution of the calcifications. We go over PAM's clinical presentation, imaging traits, diagnostic difficulties, and current therapeutic strategies. In order to provide a complete overview of this uncommon lung illness, we also evaluate relevant research.

**Key words:** Calcific Microliths, Micronodules, Pulmonary Alveolar Microlithiasis.

### INTRODUCTION

The accumulation of calcium phosphate crystals in the alveoli is a hallmark of the rare condition known as pulmonary alveolar microlithiasis (PAM).<sup>1</sup> The condition is attributed to a mutation in the SLC34A2 gene, which codes for the type IIb sodium phosphate cotransporter in type II alveolar cells.<sup>2</sup> Early on, patients typically do not exhibit symptoms, and the illness is commonly unintentionally identified through chest radiographs taken for unrelated circumstances. As the illness proceeds, patients may develop like coughing, fever, and shortness of breath. On chest radiographs, a characteristic pattern of bilateral fine sand-like calcified micronodules and a sandstorm look is typically seen.<sup>3</sup>

### CASE REPORT

A 16-year-old Pakistani woman with respiratory issues and a one-week history of fever reported to the emergency room of Sahiwal teaching hospital. When she arrived, she had the following vital signs: Blood pressure was 100/50 mmHg, pulse was 115 bpm, and respirations were 26 per minute. The temperature was 98F. Her oxygen saturation

was 75% on room air. Auscultation detected bibasilar fine crackles. The complete blood count indicated mild neutrophilic leukocytosis, and her hemoglobin level and platelet count were within normal limits. C-reactive protein was elevated at 52 mg/L. Arterial blood gas analysis at arrival revealed uncompensated respiratory alkalosis with type 1 respiratory failure. Levels of serum calcium, corrected calcium for albumin, phosphate, and parathyroid hormone were within the normal range. Liver and renal function tests showed no abnormalities. The results of a chest radiograph revealed bilaterally extensive consolidation. [Figure1].

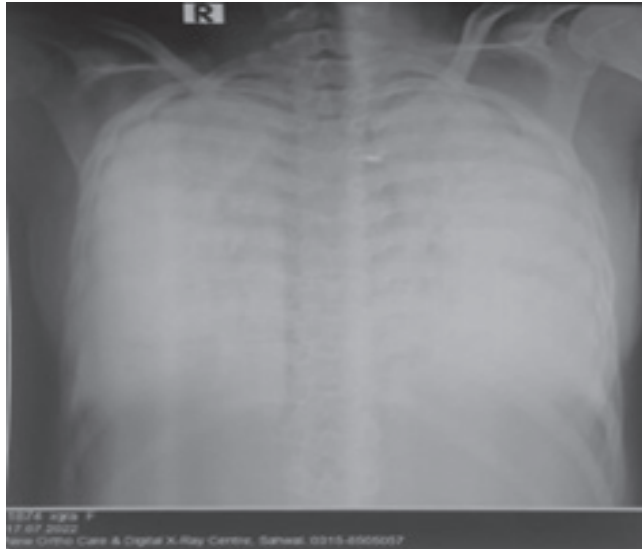The patient was found to have a severe lower respiratory tract infection with acute respiratory distress syndrome (ARDS) consequences. She was brought to the critical care unit because they needed constant oxygen assistance. The findings of a septic workup, which included testing for a respiratory viral panel, the human immunodeficiency virus, as well as sputum, urine, and blood cultures, were all unremarkable. The sputum did not contain any acid-fast bacilli, either.

1. MBBS, FCPS, Assistant Professor Pulmonology, Sahiwal Teaching Hospital, Sahiwal.  
2. MBBS, Medical Officer Pulmonology, Sahiwal Teaching Hospital, Sahiwal.  
3. MBBS, House Officer, Sahiwal Teaching Hospital, Sahiwal.  
4. MBBS, Medical Officer Pulmonology, Sahiwal Teaching Hospital, Sahiwal.  
5. MBBS, Medical Officer, Sahiwal Teaching Hospital, Sahiwal.

**Correspondence Address:**  
Dr. Ahmed Uzair  
Department of Pulmonology  
Sahiwal Teaching Hospital Sahiwal.  
rollno225@gmail.com

**Article received on:** 18/10/2023  
**Accepted for publication:** 30/12/2023

Evaluation of the chest using high-resolution computed tomography (HRCT) revealed dense interlobular thickening and widespread consolidations with a calcific density in both lungs. [Figure-2].



**Figure-1. CXR (PA) suggestive of bilateral dense consolidation.**

Lung transplantation is the main course of therapy for PAM. Unfortunately, in our patient's case, a lung transplant was not a viable option, so we opted for symptomatic management. During the testing process, the patient's siblings were examined, and two of the younger sisters (six & twelve years old) exhibited the same radiographic findings, yet

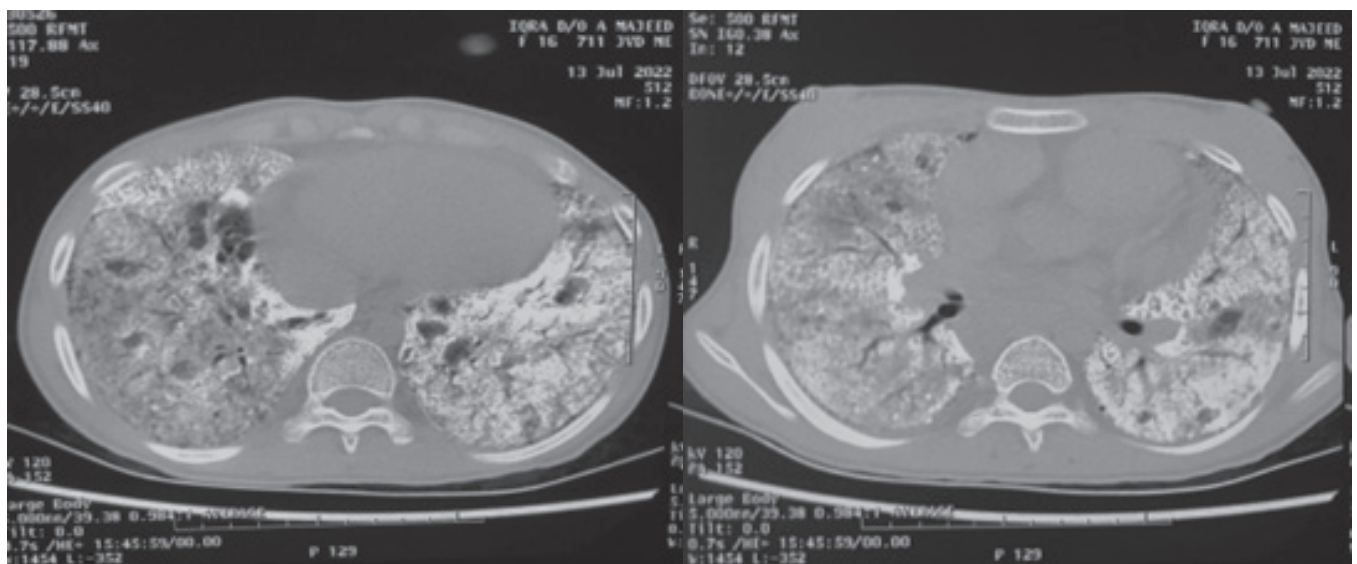
they remained asymptomatic [Figure-3].

## DISCUSSION

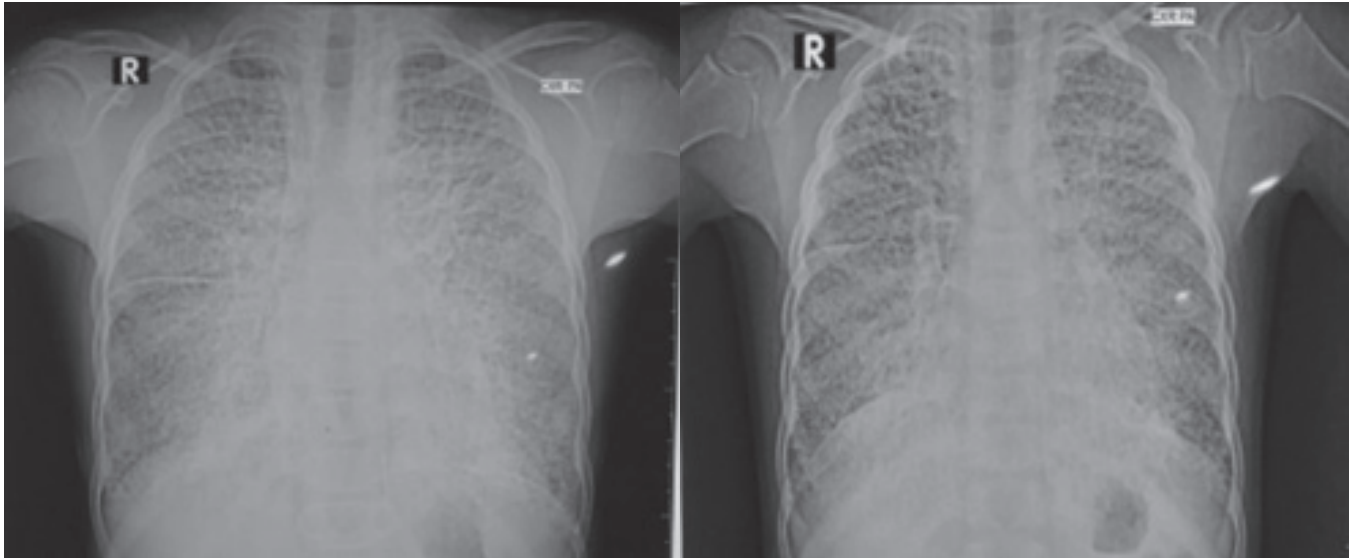
A prolonged accumulation of microliths within the alveoli characterizes the uncommon genetic lung illness PAM. The type IIb sodium phosphate cotransporter in type II alveolar cells, encoded by the SLC34A2 gene, is connected to this syndrome. As

a result of this mutation's loss in phosphate absorption, calcium chelation in the extracellular fluid results in the production of microliths inside the alveoli. PAM can affect people of any age, however it typically affects people in their twenties and thirties. As was the case with our patient, a Pakistani girl in her teen years of life with no prior family history, the illness has a small male preponderance, and only 37% of patients have a positive family history of PAM.<sup>4</sup>

Early on, PAM sufferers may not exhibit any symptoms or just exhibit minor ones like a cough that doesn't produce mucus or shortness of breath. The course of the illness might differ, and some individuals may have stable radiological results and symptoms. PAM can cause pulmonary fibrosis, cor pulmonale, and respiratory failure, although it progresses gradually.



**Figure-2. High-resolution chest computed tomography scans showing bilateral dense interlobular thickening and extensive consolidations with calcific density.**



**Figure-2. High-resolution chest computed tomography scans showing bilateral dense interlobular thickening and extensive consolidations with calcific density.**

Finding the hallmark radiological and histological characteristics of PAM is usually the first step in diagnosing it. Typically affecting the middle and lower lung zones, bilateral, sand-like calcified micronodules with a sandstorm look are frequently shown on chest radiography. In infants with PAM who are asymptomatic, high-resolution computed tomography (HRCT) of the chest reveals non-calcified micronodules in both lungs. As the illness progresses, many of the micronodules (1 mm) populate the lung fields, causing dense consolidations, ground glass opacities, and calcified micronodular interlobular septal thickening, giving the appearance of “crazy paving”.<sup>5</sup> Although radiographic signs might be suggestive, bronchoalveolar lavage and lung biopsy are necessary for the diagnosis of PAM. Since the SLC34A2 gene is expressed in several organs, extrapulmonary calcifications, such as nephrolithiasis, seminal vesicle calcifications, and medullary calcinosis, may develop.

Presently, there is no curative treatment for PAM. The management mainly focuses on symptom control and disease progression slowdown through systemic corticosteroids, sodium thiosulfate (a calcium chelating agent), and a low phosphate diet. The only curative option for PAM is lung transplantation and there have been no reported cases of recurrence following

transplantation.<sup>6</sup>

## CONCLUSION

PAM is an unusual condition marked by the buildup of lung calculi that resemble bones, leading to a gradual decline in respiratory function. Unfortunately, there is currently no known effective treatment and management mainly involves supportive measures, with lung transplantation considered for those with progressive conditions. The identification of the genetic basis of PAM represents a significant breakthrough, offering valuable insights into its pathogenesis and paving the way for potential biomarkers and therapies in future. Raising awareness among doctors about the characteristic radiological and pathological findings can facilitate early diagnosis.

## PATIENT CONSENT

Informed consent was obtained from the patient.





**Copyright© 23 Dec, 2023.**

## REFERENCES

1. Kosciuk P, Meyer C, Wikenheiser-Brokamp KA, McCormack FX. **Pulmonary alveolar microlithiasis.** *European Respiratory Review.* 2020; 29(158).
2. Huqun, Izumi S, Miyazawa H, Ishii K, Uchiyama B, Ishida T, et al. **Mutations in the SLC34A2 gene are associated with pulmonary alveolar microlithiasis.** *American Journal of Respiratory and Critical Care Medicine.* 2007; 175(3):263-8.

3. Lauta VM. **Pulmonary alveolar microlithiasis: An overview of clinical and pathological features together with possible therapies.** Respiratory Medicine. 2003; 97(10):1081-5.
4. Castellana G, Castellana G, Gentile M, Castellana R, Resta O. **Pulmonary alveolar microlithiasis: Review of the 1022 cases reported worldwide.** European Respiratory Review. 2015; 24(138):607-20.
5. Deniz O, Ors F, Tozkoparan E, Ozcan A, Gumus S, Bozlar U, et al. **High resolution computed tomographic features of pulmonary alveolar microlithiasis.** European Journal of Radiology. 2005; 55(3):452-60.
6. Edelman JD, Bavaria J, Kaiser LR, Litzky LA, Palevsky HI, Kotloff RM. **Bilateral sequential lung transplantation for pulmonary alveolar microlithiasis.** Chest. 1997; 112(4):1140-4.

### AUTHORSHIP AND CONTRIBUTION DECLARATION

No.	Author(s) Full Name	Contribution to the paper	Author(s) Signature
1	Muhammad Waseem	Overall idea, Data collection, Final review.	
2	Ahmed Uzair	Design, Drafting, Critical revision.	
3	Nauman Ijaz Bhatti	Design, Drafting, Critical revision.	
4	Muhammad Sajawal	Design, Drafting, Critical revision.	
5	Amna Abid	Design, Drafting, Critical revision.	