



## Evaluation of location of mental foramen using cone-beam computed tomography in Pakistani population.

1. BDS, FCPS (OMFS)  
Assistant Professor Oral & Maxillofacial Surgery  
University College of Medicine and Dentistry, The University of Lahore.
2. BDS, FCPS (OMFS)  
Assistant Professor Oral & Maxillofacial Surgery  
University College of Medicine and Dentistry, The University of Lahore.
3. BDS, FCPS (OMFS),  
FFDRCS (OS/OM)  
Assistant Professor Oral & Maxillofacial Surgery  
University College of Medicine and Dentistry, The University of Lahore.
4. BDS, MDS (OMFS)  
Assistant Professor Oral & Maxillofacial Surgery  
Azra Naheed Dental College Lahore.
5. BDS, FCPS (OMFS), FCPS  
(Prosthodontics), MCPS(Perio)  
HOD/Professor Oral & Maxillofacial Surgery, King Edward Medical University Lahore.
6. MBBS  
Medical Officer  
THQ Hospital Sangla Hills.

### Correspondence Address:

Dr. Tooba Saeed  
Department of Oral & Maxillofacial Surgery  
University College of Medicine and Dentistry,  
The University of Lahore.  
[tooba.saeed@ucd.uol.edu.pk](mailto:tooba.saeed@ucd.uol.edu.pk)

### Article received on:

28/09/2020

### Accepted for publication:

23/01/2021

Tooba Saeed<sup>1</sup>, Tahmasub Faraz Tayyab<sup>2</sup>, Ahmad Liaquat<sup>3</sup>, Muhammad Adnan Akram<sup>4</sup>, Nabeela Riaz<sup>5</sup>, Hafiz Abdulhannan<sup>6</sup>

**ABSTRACT... Objectives:** The location of mental foramen (MF) is significant in many surgical and nonsurgical procedures related to the mandible to avoid the injury of the mental nerve. The location of mental foramen is considered variable in different populations and even in different groups of population. We used CBCT to locate the position of the mental foramen. As high-resolution three-dimensional images of CBCT reveal anatomic structures more clearly, it improves mental foramen detection, offering advantages over two-dimensional radiological images. **Study Design:** Cross-sectional Descriptive study. **Setting:** Department of Oral & Maxillofacial Surgery, University College of Medicine & Dentistry, The University of Lahore. **Period:** July 2017 to Dec 2019. **Material & Methods:** A sample of 230 CBCT scans was obtained from the data already available in the department of Oral & Maxillofacial Surgery. The horizontal position of MF was analyzed utilizing 3D images of CBCT at 6 positions concerning the long axis of mandibular premolars and molars. **Results:** Ninety-six (41.7%) mental foramen were located at position 3, i.e., between the first and second premolars. Moreover, this was the most common location of the mental foramen. Followed by position 4 (in line with the long axis of the second premolar) 90(39.1%). A statistically significant relationship between the gender of the patient and the location of the mental foramen was seen. **Conclusion:** The location of mental foramen is variable; care should be taken in performing procedures in the area of the mental foramen to avoid iatrogenic injury of the mental nerve. Our results are different from previous studies conducted in the Pakistani population.

**Key words:** CBCT For Implants, Mandible Surgeries, Mental Foramen Location.

**Article Citation:** Saeed T, Tayyab TF, Liaquat A, Akram MA, Riaz N, Abdulhannan H. Evaluation of location of mental foramen using cone-beam computed tomography in Pakistani population. *Professional Med J* 2021; 28(9):1341-1345. <https://doi.org/10.29309/TPMJ/2021.28.09.6111>

## INTRODUCTION

In many clinical situations, knowing the location of the foramen is required, particularly in the maxillofacial region, to administer nerve blocks for both surgical and nonsurgical procedures in order to avoid nerve injury.<sup>1</sup> The inferior alveolar nerve emits through mental foramen (MF) on the lateral surface of the anterior mandible and continues in soft tissue as a mental nerve.<sup>2,3</sup> The sensory distribution of the mental nerve divides between three smaller branches. One of them innervates the skin of the chin. While the other two branches provide sensory innervation to the labial mucosa anterior to the first molar, gingivae and ipsilateral lower lip.<sup>4,5</sup> Thus knowing the location of MF is crucial to gain adequate dental anesthesia and to avoid iatrogenic injury during

surgical procedures such as fracture reduction in parasymphysis and body region of the mandible orthognathic surgeries, surgical removal of roots and teeth, placement of dental implants, removal of the cyst, and tumors. Similarly, periapical, periodontal, endodontic, and dental implant placement in the anterior mental region also carries a risk of damage to this neurovascular bundle.<sup>6,7</sup>

Previously conducted studies show variation in the position of MF from individual to individual and its relation with different ethnic groups. The majority of studies conducted to determine the location of MF identified it to be located between first and second premolars in the majority of populations.<sup>7,8</sup> Many authors have classified the

location of MF according to its anteroposterior position in relation to premolars and molars. Classifications described by Pyun et al.<sup>3</sup> and Tebo et al.<sup>8</sup> are frequently used to mark the location of MF.

Most studies have been conducted on dry skulls or by using panoramic radiographs to establish the position of MF.<sup>9,10</sup> However, the identification of MF is not always possible using two-dimensional panoramic radiographs as visualization of panoramic images is influenced by MF size, trabecular pattern, MF emergence, and patient's age. More studies were conducted in the last decade in order to identify the exact position of MF by using the newly emerging technology of Cone-beam computed tomography (CBCT).<sup>11,12</sup> As high-resolution three-dimensional images of CBCT reveal anatomic structures more clearly, it's being increasingly used as a diagnostic and planning tool in dentistry. Thus, a CBCT image improves MF depiction, offering advantages over two-dimensional radiological images.<sup>13</sup>

A few studies have been conducted in the Pakistani population to establish the location of the MF. Two studies have used a panoramic radiograph,<sup>14,15</sup> while one has used CBCT to determine the exact position of MF.<sup>16</sup>

This study aimed to determine the horizontal position of MF in the Pakistani population by using CBCT to avoid mental nerve injuries during various maxillofacial surgical procedures like dental implant placement in mental nerve region and plating of the mandible in trauma or orthognathic cases.

## MATERIAL & METHODS

This retrospective study was conducted after approval from the university ethical board committee (UCD/ERCA/19/03B). The data of 230 CBCT scans were reviewed, which were performed in the radiology Department of Oral and Maxillofacial Surgery, from a period of July 2017 to Dec 2019. All images were taken with the same protocol using Planmeca Romexis 3D max version 5.2R in 12-bit grayscale and a voxel size of 0.3 mm.

The inclusion criteria for data collection were (1) CBCT should only include ethnic Pakistani individuals. (2) Presence of premolars and first molar at the analyzed site. (3) Regular bone pattern adjacent to MF without any radiolucent/radiopaque lesion.

Six positions were evaluated to determine the horizontal location of the MF, 1- mesial to the first premolar; 2- in line with the long axis of the first premolar; 3- between the first and second premolars; 4- in line with the long axis of the second premolar; 5- between the second premolar and the first molar; 6- distal to the first molar.

Data were entered into SPSS version 22. A descriptive variable like age was determined as mean, minimum, and maximum. The frequency of gender and location of MF at each location was determined in percentages. To assess the relationship between side of mandible and gender with the location of the mental foramen, pearson chi-square test was used and 0.05 was set as a level of significance.

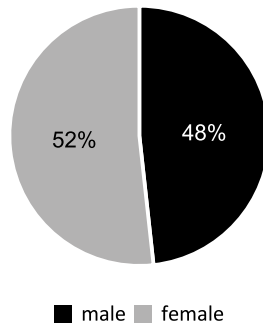
## RESULTS

Among 230 evaluated CBCT images, the mean age of patients was  $32 \pm 16$  years. The minimum age of patients was 14, while the maximum was 76. Of these, 111(48.3 %) were males, and 119 (51.7%) were females. (Figure-1) MF was not absent in any of these cases. From these 230 CBCT images, 130 (57%) right and 100 (43%) left sides were selected to locate MF.

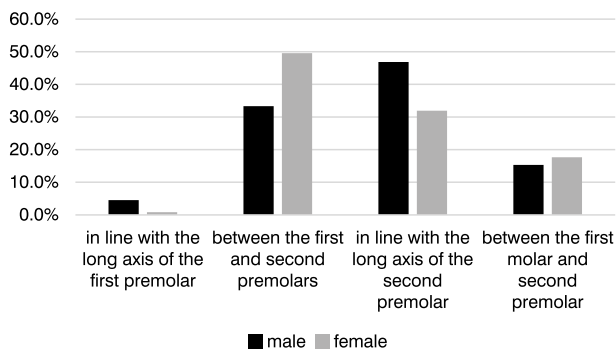
Ninety-six (41.7 %) MF was located at position 3, i.e., between the first and second premolars. Position 3 was the most common location of the MF followed by position 4 (in line with the long axis of the second premolar) 90 (39.1%), and position 5 (between the first molar and second premolar) 38 (16.5%). Only 6 (2.6%) images had MF in line with the long axis of the first premolar (position 2). However, MF was not located either mesial to the first premolar or distal to the first molar.

The side of the mandible did not significantly affect the location of MF with a p-value of 0.95. In males,

the most frequent location was position 4 (in line with the long axis of the second premolar), 46.8%, while in females, it was position 3 (between the first and second premolars) 49.6%. A statistically significant relationship between the gender of patients and the location of MF with a p-value of 0.018 was seen. (Figure-2).



**Figure-1. Gender of patients.**



**Figure-2. Position of MF both in males and females.**

## DISCUSSION

Knowledge regarding the location of MF is deemed necessary in clinical practice. Gaining adequate mental nerve anesthesia depends on the administration of local anesthetic agents at a particular location. Many different procedures related to oral surgery can cause mental nerve injury if care should not be taken to identify the location of the MF. Surgical trauma can cause paresthesia of orofacial regions. Similarly, a familiarity with the location of MF also helps in endodontic and diagnostic procedures. Moreover, it could also aid in inferring the anatomical benchmarks in forensic dentistry.

Many studies have evaluated the size, shape, position and distance of MF from adjacent

anatomic structures.<sup>3</sup> The literature emphasizes the significance of establishing MF's location to avoid iatrogenic injuries of the mental nerve.<sup>14</sup>

In the literature, the position of the MF was investigated in different ways and different populations. Budhiraja et al.<sup>17</sup> and Ilayperuma et al.<sup>18</sup> evaluated it on dry skulls, while others used different radiographic techniques like panoramic<sup>14,15</sup> and CBCT.<sup>3,12</sup>

In this study, we considered the CBCT technology to examine the horizontal location of MF. The most common location of MF is between the apices of first and second premolars (41.7%). This is in accordance with the studies on Brazilian (Oliveira Junior et al.<sup>19</sup> and British (Currie et al.<sup>20</sup>

On the other hand, other studies assessing MF location falls within our second most common position(39.1%) for MF, that was below the apex of second mandibular premolars; these were the ones conducted on Labinese Aoun G et al.<sup>8</sup> Iranian (Khojastepour et al.<sup>3</sup> Saudi Arabian (Al-Mahalawy et al.<sup>12</sup> Sri Lankan (Ilayperuma et al.<sup>18</sup>

The study conducted by Oliveira R et al. is also in agreement with our study. MF was frequently located between the first and second premolars (44.4%) followed by the position below the second lower premolar (40.8%).<sup>11</sup>

Our results are in a match to the study conducted on 400 Iranian populations by Haghanifar and Rokouei,<sup>21</sup> using orthopantomogram to determine the position of MF; they found that in most people, MF is located between first and second premolar (47.2%).

However, the study conducted on a group of the Pakistani population by utilizing a panoramic radiograph, the location of MF below the second premolar(47.2%) was the first most common position while the position between the first and second premolars(40.4%) was afterward.<sup>15</sup> The results are comparable to our findings. Moreover, the results of the second radiographic study conducted by Khalid M et al.<sup>14</sup> which was also conducted on Pakistani people, are in contrast

to our results. This showed the most common location of MF was below the first premolar (45.71%).<sup>14</sup>

A recent study conducted in the Pakistani population by using CBCT found the most common MF location is below the mandibular second premolar, followed by the position between the second premolar and first molar. This study also showed that the most common location for both males and females was below the second premolar.<sup>16</sup> While, our study revealed that in males most prevalent location was below the apex of the second premolar, while in females, it was between the first and second premolars.

Ethnicity also affects the position of MF. Santini et al.<sup>22</sup> concluded a study on people of different ethnic backgrounds to determine ethnic relations with the position of MF. They studied Chinese, Indians and European cadaveric skulls and revealed that in Europeans and Indians, MF is mostly located between first and second premolars, whereas in Chinese, the common location was below the second premolar. Their work shows how ethnicity affects the position of MF. Our findings in the Pakistani Population-based on CBCT are in alignment with this study.

The limitations of our study are that it was conducted in only one hospital. Pediatric and geriatric patients were not included. Data of a larger group of the population from more hospitals, including various regions of Pakistan, should be evaluated to overcome these limitations.

## CONCLUSION

In our study, the most common location of MF was between the first and second premolars. There was a significant difference in the position of MF among females and males. As the location of MF is variable, care should be taken in performing procedures in the vicinity of MF. Our results are different from previous studies conducted in the Pakistani population. More studies should be encouraged to get a larger sample size in our population to get sufficient information.






Copygith© 23 Jan, 2021.

## REFERENCES

1. Shah S, Vaze S, Kinhal K. **A variation in the position of the mental foramen: A Case Report.** J Maxillofac Oral Surg. 2010; 9(3):307–9.
2. Shrestha P, Maskey S, Mansur DI, Humagain M. **Radiographic study of mental foramen in nepalese population.** J Nobel Med Coll. 2019; 8(1):8–11.
3. Khojastepour L, Mirbeigi S, Mirhadi S, Safaee A. **Location of mental foramen in a selected Iranian population: A CBCT assessment.** Iran Endod J. 2015; 10(2):117–21.
4. Sheikhi M, Kheir MK. **CBCT Assessment of mental foramen position relative to anatomical landmarks.** Int J Dent. 2016; 2016:1–6.
5. Ravi P, Elavenil P, Sarkar S, Raja KV. **Anatomical variant of the mental nerve and its foramen.** SRM J Res Dent Sci 2017 Apr 1;8(2):85.
6. Naitoh M, Nakahara K, Hiraiwa Y, Aimiya H, Gotoh K, Arijji E. **Observation of buccal foramen in mandibular body using cone-beam computed tomography.** Okajimas Folia Anat Jpn. 2009; 86(1):25–9.
7. D'Dharan SR, Uma Maheswari TN. **Evaluation of position of mental foramen using cbct among chennai population: A retrospective study.** Int J Clin Dent. 2015; 8(4):295–300.
8. Aoun G, El-Outa A, Kafrouny N, Berber A. **Assessment of the mental foramen location in a sample of fully dentate lebanese adults using cone-beam computed tomography technology.** Acta Inform Medica. 2017; 25(4):259–62.
9. Vimala V, Rohinidevi M, Mekala D. **Study of anatomical variations of mental foramen in dry adult human mandibles and its clinical importance.** IOSR-JDMS. 2015; 14(9):40–4.
10. Rothe TM. **Radiographic position of the mental foramen.** Anat Sci. 2018; 1(3).
11. dos Santos Oliveira R, Rodrigues Coutinho M, Kühn Panzarella F. **Morphometric analysis of the mental foramen using cone-beam computed tomography.** Int J Dent. 2018 Mar 26; 2018.
12. Al-Mahalawy H, Al-Aithan H, Al-Kari B, Al-Jandan B, Shujaat S. **Determination of the position of mental foramen and frequency of anterior loop in Saudi population. A retrospective CBCT study.** Saudi Dent J. 2017; 29(1):29–35.

13. Li Y, Yang X, Zhang B, Wei B, Gong Y. **Detection and characterization of the accessory mental foramen using cone-beam computed tomography.** Acta Odontol. Scand. 2018 Feb 17; 76(2):77-85.
14. Khalid M, Manzoor F, Rasheed A, Salman S, Khawaja SH, Ahmed A. **Radiological locations of mental foramen in local population.** APIMS. 2019 Dec 28;15(3):114-8.
15. Haider SM. **Panoramic radiographic study of mental foramen in a selected Pakistani population.** Int J Oral Maxillofac Surg. 2007 Nov 1; 36(11):1033.
16. Ahmed QN, Khan MN, Rehman AU, Shahid A, Ghafoor W, Kiani SG. **A cone-beam computed tomography based assessment of mental foramen position.** PAFMJ. 2019 Feb 28; 69(1):102-06.
17. Budhiraja V, Rastogi R, Lalwani R, Goel P, Bose SC. **Study of position, shape, and size of mental foramen utilizing various parameters in dry adult human mandibles from North India.** ISRN Anat. 2013; 2013:1-5.
18. Ilayperuma I, Nanayakkara G, Palahepitiya N. **Morphometric analysis of the mental foramen in adult Sri Lankan mandibles.** Int J Morphol. 2009; 27(4):1019-24.
19. dos Santos Oliveira R, Maria Gomes Oliveira A, Cintra Junqueira JL, Kühl Panzarella F. **Association between the anatomy of the mandibular canal and facial types: A cone-beam computed tomography analysis.** Int J Dent. 2018 Sep 10; 2018.
20. Currie CC, Meechan JG, Whitworth JM, Carr A, Corbett IP. **Determination of the mental foramen position in dental radiographs in 18-30 year olds.** Dentomaxillofac Radiol. 2016 Jan; 45(1):20150195.
21. Haghanifar S, Rokouei M. **Radiographic evaluation of the mental foramen in a selected Iranian population.** Indian J Dent Res. 2009 Apr 1; 20(2):150.
22. Santini A, Alayan I. **A comparative anthropometric study of the position of the mental foramen in three populations.** Br Dent J. 2012 Feb; 212(4):E7.

### AUTHORSHIP AND CONTRIBUTION DECLARATION

Sr. #	Author(s) Full Name	Contribution to the paper	Author(s) Signature
1	Tooba Saeed	Idea, Study plan, execution, preparation of final draft.	
2	Tahmasub Faraz Tayyab	Collection of data, Data analysis.	
3	Ahmad Liaquat	Writing discussion, Final review.	
4	M. Adnan Akram	Literature review.	
5	Nabeela Riaz	Final draft critical review.	
6	Hafiz Abdulhannan	Data analysis, review of final draft.	