


ORIGINAL

PROF-1277

## SENTINEL LYMPH NODE; LYMPHATIC MAPPING IN PATIENTS WITH BREAST CARCINOMA

**DR. SADIA HAMEED, DCP, M.PHIL**

Assistant Professor, Department of Pathology,  
Faculty of Health Sciences,  
The University of Faisalabad, Faisalabad

**DR. SABIHA RIAZ, FRC PATH**

Professor of Pathology,  
Fatima Memorial Medical & Dental College,  
Lahore

**DR. ARIF HUSSAIN, MCPS, M.PHIL**

Demonstrator, Department of Pathology,  
Punjab Medical College, Faisalabad

**ABSTRACT...** [sadiahameed@yahoo.com](mailto:sadiahameed@yahoo.com) **Objective:** To assess the efficacy of a localization technique for the sentinel lymph node in patients with early breast carcinoma using 1% isosulphan blue. **Study Design:** Prospective study **Place and Duration:** Departments of Pathology, Punjab Medical College Faisalabad and Sheikh Zayed Hospital, Lahore and Departments of Surgery, Allied & DHQ Hospitals, Faisalabad from July 2002 – June 2003. **Patients and Methods:** 1% Isosulphan blue was used to identify the sentinel node in cases of early (T1 & T2) breast cancer. The dye was injected just before the incision was made. The area was massaged. Mastectomy was done. The sentinel node was identified by following the blue track to the first coloured lymph node. This was removed and submitted separately for histopathology along with the mastectomy specimen. **Results:** The procedure was performed in 95 cases. SLN were identified in 80 (84%) patients. The mean age was 43.99 years. Majority of the tumours were located in the right breast in the upper outer quadrant. One SLN was identified in 93%, 2 in 3% and 3 were noted in 4% of the cases. **Conclusion:** Injection of 1% isosulphan blue around the tumour is an effective method for isolation of the SLN in selected cases. It saves the patient of the side effects of axillary clearance in node negative cases.

**Key words:** sentinel lymph node; breast cancer; cancer; isosulphan blue.

### INTRODUCTION

Sentinel lymph node (SLN) is the first lymph node, or the echelon lymph node, on the direct lymphatic drainage pathway of a tumour. The term "sentinel node" was first used in 1960 with reference to cancer of the parotid gland.<sup>1</sup> Cabanas,<sup>2</sup> apparently unaware of the previous report, used the phrase in 1977 for staging of penile carcinoma. He demonstrated that using a lymphatic

mapping technique one could identify the "sentinel node". In 1992, Mortan and associates<sup>3</sup> demonstrated the validity of the technique in melanoma. Soon other workers started to use this technique in cases with breast cancer employing various lymphatic mapping methods<sup>4,5</sup>.

Krag and his colleagues<sup>6</sup> used the radiolocalization technique in the isolation of the SLN, while Giuliano et al<sup>5</sup> were the first to use a blue dye for the isolation of the

SLN. A combination technique using both the radioisotope and the blue dye was used for the first time by Albertini and workers<sup>4</sup>.

Isolation of a SLN free of tumour obviates the need of axillary clearance so that the patient is spared of side effects of axillary clearance<sup>7</sup>. The technique of SLN biopsy has the potential of changing the standard of surgical care of the breast cancer patients<sup>8,9</sup>. The initial route of metastasis in carcinoma breast is via the lymphatics to the regional lymph nodes. So the patients who do not have regional metastasis are unlikely to benefit from axillary clearance and may suffer from troublesome post operative lymphoedema of the arm.

Early detection of spread of carcinoma of the breast with SLN isolation, would thus help in improving the quality of life in such patients. The standard axillary lymph node dissection is associated with some morbidity such as lymphoedema of the ipsilateral extremity, frozen shoulder syndrome, long term sensory abnormality related to resection or manipulation of the intercostobrachial nerves, cellulitis, seroma formation etc<sup>10</sup>. Thus, if the SLN hypothesis is true, then the need for axillary clearance is obviated in cases in which the SLN is clear of the tumour, and so the patient would be saved of all the side effects.

The mapping of the SLN is a simple, inexpensive technique that has the potential to decrease surgical morbidity. Early detection of a disease free axilla by this process will improve the standard of life in such patients. This study was carried out to assess the efficacy of a localization technique using 1% isosulphan blue in patients with early breast carcinoma in our setup.

## MATERIALS & METHODS

During the study period, the localization technique was employed in 95 cases. All the cases included in the study were females. The mean age of the women was  $43.99 \pm 11.97$  and the mode was 40 years (Figure 1).

The study was conducted in the Departments of Pathology, Punjab Medical College Faisalabad; Sheikh Zayed Hospital, Lahore and Departments of General Surgery, Allied & DHQ Hospitals, Faisalabad from July 2002 to June 2003. Patients with unifocal breast

carcinoma, diagnosed on FNAC or lumpectomy, where the primary tumour size was less than 5 cm (T1 & T2), without distant metastases, were included in the study. History was taken and examination was done and pertinent findings noted.

The selection criteria for inclusion in this study was; women who had mastectomies with axillary clearance for unifocal breast carcinoma having primary size of tumour up to 5 cm (T1 & T2) in which SLN localization was done and at least 6-7 lymph nodes had been removed. Patients with the following criteria were excluded: multi-centric breast carcinoma, patients having previous history of breast or axillary surgery, previous history of treatment of breast carcinoma with chemotherapy or radiotherapy.

After anaesthetizing the patient and before making the incision, approximately 5 ml of 1% isosulphan blue was injected around the tumor or in the biopsy cavity if a lumpectomy had been done. The area was massaged to improve the lymphatic uptake of the dye. Routine mastectomy with axillary clearance was performed in all cases. The SLN was visualized by following the blue stained lymphatic tract to a blue coloured lymph node.

This was isolated, removed and placed in a separate container which was labeled. The rest of the mastectomy specimen was placed in a separate container. Both specimens were then submitted for histopathology. Statistical analysis of the results was done using SPSS (Statistical Package for Social Sciences) version 12.

## RESULTS

Fifty (52.6%) of the cases had cancer on the right side and 45(47.4%) on the left. Mean duration of the lump was 139.46 ( $\pm 170.29$ ) days, the range being 15-730 days. The mean size of the lump on clinical examination was 3.39 x 2.82 cm (Table I). 66% of the tumours were in the upper outer quadrant (Figure 2).

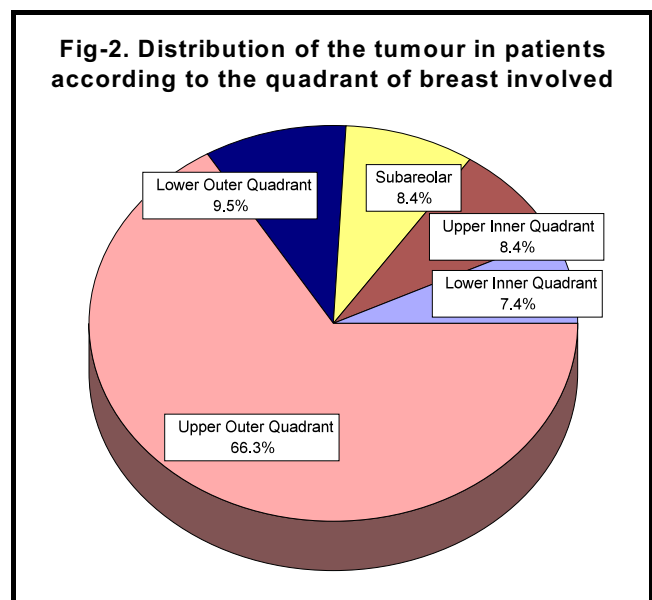
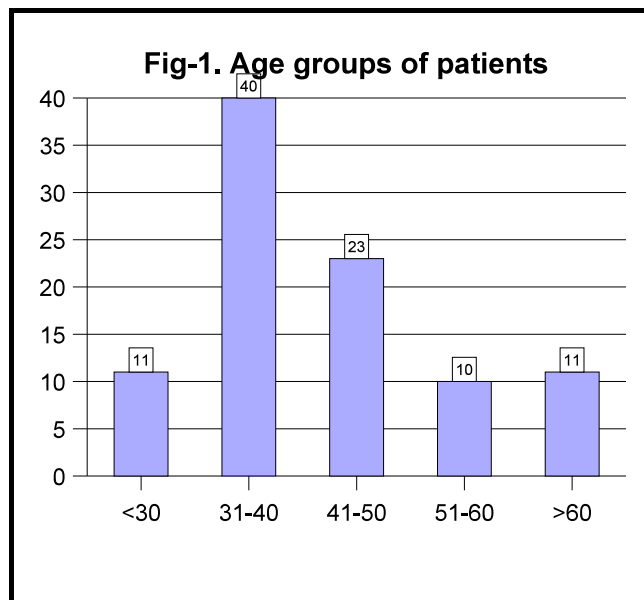
Frequency of tumors in the other quadrants ranged from 7 to 10%. The SLN was successfully isolated in 80(84.2%) cases. Of these 80 cases, one SLN was identified in 93.7% while 2 were identified in 2.5% and 3 were noted in 3.8% of the cases. According to the clinical stage, 30(37.5%) were of T1 stage and 50(62.5%) of T2.

In those 15 cases in which the SLN was not identified, the lump was located in the inner half of the breast. 78(97.5%) had infiltrating ductal carcinoma while there was one case each of mucinous carcinoma and in situ lobular carcinoma on histopathology.

Size of lump	Mean (SD)	Mode	Range
Length lump (cm)	3.39±1.10	3	1 - 5
Breadth of lump (cm)	2.82±1.01	3	1 - 5

Study	No. of pts	Mapping Technique	Success Rate(%)	False -ve Rate (%)
Krag et al	22	T	81.8%	0%
Giuliano et al	174	B	65.5%	4.4%
Schneebaum et al	15	B/T	86.7%	7.7%
Neville et al	27	B	88.9%	0%
Meijer et al	30	T	93.3%	0%
Albertini et al	62	B/T	91.9%	0%
Giuliano et al	107	B	93.5%	0%
Veronesi et l	160	T	97.5%	2.5%
Cox etal	700	B/T	95.0%	0.841%
Present study	95	B	84%	0%

*B = Blue dye; T = Technetium-labeled sulphur colloid*



## DISCUSSION

Axillary lymph node dissection (ALND) is regarded as a reliable method of assessing nodal status and treating regional disease<sup>10</sup>. Patients without histologically involved lymph nodes do not derive a therapeutic benefit from ALND and must deal with the potential morbidity of the procedure<sup>11</sup>. Recently the need for ALND in patients with early breast carcinoma has been questioned because about 75% of axillary nodes in these cases are disease free<sup>12</sup>. Lymphatic mapping, initially developed to aid in the treatment of melanoma, has gained unprecedented momentum in the treatment of breast carcinomas since the first published Breast Cancer Multicenter Study in 1998<sup>13</sup>.

The concept of the SLN is based on the orderly progression of tumour cells within the lymphatic system. Metastasis to regional lymph nodes is not a random event and the primary draining node or the SLN is the first lymph node to contain the metastases. Thus, sentinel lymphadenectomy is a highly accurate technique for identifying axillary metastases from invasive breast carcinoma<sup>14</sup>. In competent hands the success rate is high. In our study, we were able to isolate the SLN in 84% cases. This compares favourably with the various reported series (Table II). Performance of sentinel node biopsy for breast cancer is not difficult. However, its early proponents recognized that the technique could not be mastered in a single course. They further recognized that the implications of improper use of such technology are potentially catastrophic, in that a treatment opportunity may close prematurely in a patient whose SLN is incorrectly labeled as negative<sup>15</sup>.

Various dyes have been used by different researchers over the time but the use of most of them has been abandoned as they gave unsatisfactory results. Methylene blue, a water-soluble dye, proved to have poor lymphatic uptake and caused background staining of the tissues. Cyalume, a fluorescent dye has been used and, although it allowed good visualization of the lymphatics, it also leaked into the interstitial tissue resulting in marked background fluorescence. Isosulphan blue has been recommended as the best agent for lymphatic mapping as it quickly enters the lymphatic channels and is readily visualized in the vessels with minimal diffusion

into the soft tissues<sup>16,17</sup>. In our study we preferred to use 1% isosulphan blue. No allergic reaction to the blue dye occurred. However, there was blue stained urine and stool. This effect lasted for no longer than 24 hours and was harmless. None of the other reported side effects as by Leong et al<sup>18</sup> like anaphylaxis, cardiovascular collapse, bronchospasm, urticaria, rash gastrointestinal symptoms and pulmonary oedema were seen in our cases.

Failure of identification of the SLN can be due to a number of reasons. These include a learning curve regarding the localization technique on the part of the surgeons. It has been reported that the isolation rate does increase as the surgeon attains proficiency in the procedure<sup>16,19,20</sup>. Another factor is the location of the tumour in the inner half of the breast. In some of these cases the main drainage of the affected area is to the internal mammary nodes<sup>4,21</sup>. Blockage of the lymphatic channels by the tumour cells is another factor to be considered in cases in which the localization is not possible<sup>8,16,22</sup>. Still another factor for non localisation is the injection of the dye into a biopsy cavity with a mature lining<sup>8</sup>.

In this study isosulphan blue was used because of its good visualization of the lymphatic tract and least possible side effects for the patient. It is also simple to use and less costly. Haider and colleagues<sup>17</sup> used radioisotope labeled albumin along with 1% isosulphan blue(5) and isosulphan blue alone (10) for localization of the sentinel lymph node in a total of 15 patients. They found that the identification rate by both methods was comparable. Kanwal et al.<sup>23</sup> also reported 30 cases in which 1% isosulphan blue was used successfully for isolation of the sentinel lymph node in females. Our study described a large series of cases using isosulphan blue dye only with high success.

## CONCLUSION

This study reveals that lymphatic mapping is technically possible in our setup in patients with breast carcinoma. The technique is simple and cost effective. The dye is harmless without any significant side effects. It saves the patient from the extensive side effects of axillary clearance in whom the axilla is free of disease. This

procedure allows the pathologist to focus the histological examination in 1-2 nodes potentially increasing the yield of positive dissection. It is highly recommended for use in our country.

## REFERENCES

1. Boolbol SK, Fey JV, Borgen PI, Heerdt AS, Montgomery LL, Paglia M, *et al.* **Intradermal isotope injection: A highly accurate method of lymphatic mapping in breast carcinoma.** *Ann Surg Oncol* 2001; 8(1): 20-24.
2. Cabanas R. **An approach for the treatment of penile carcinoma.** *Cancer* 1977;39:456-66.
3. Morton DL, Wen DR, Wong JH, Economou JS, Cagle LA, Foshag LJ, *et al.* **Technical details of intraoperative lymphatic mapping for early stage melanoma.** *Arch Surg* 1992; 127(4): 392-9.
4. Albertini JJ, Lyman GH, Cox C *et al.* **Lymphatic mapping and sentinel lymph node biopsy in the patient with breast cancer.** *JAMA* 1996;276:1818-22.
5. Giuliano AE, Kirgan DM, Guenther JM, Morton DL. **Lymphatic mapping and sentinel node biopsy in the patient with breast cancer.** *Ann Surg* 1994;220:391-401.
6. Krag DN, Weaver DL, Alex JC, Fairbank JT: **Surgical resection and radiolocalization of sentinel lymph node in breast cancer using a gamma probe.** *Surg Oncol* 1993;2:335-40.
7. Ozaslan C, Kuru B. **Lymphoedema after treatment of breast cancer.** *Am J Surg* 2004 Jan;187(1): 69-72.
8. Cox CE, Bass SS, Boulware D, Ku NK, Berman C, Reintgen DS. **Implementation of new surgical technology: Outcome measures for lymphatic mapping of breast carcinoma.** *Ann Surg Oncol* 1999; 6(6): 553-561.
9. Singh Ranger G, Mokbel K. **The evolving role of sentinel lymph node biopsy for breast cancer.** *Eur J Surg Oncol* 2003 Jun;29(5):423-5.
10. Sakorafas G, Tsiotou A. **Sentinel lymph node biopsy in breast cancer.** *Am Surg* 2000; 66: 667-674.
11. Lin PP, Allison DC, WAinstock J. **Impact of axillary lymph node dissection on the therapy of breast cancer patients.** *J Clin Oncol* 1993;11:1536-44.
12. Nogushi M, Taniya T, de Aretxabala X *et al.* **The significance of regional lymph node dissection in the surgical management of breast cancer.** *Jpn J Surg* 1989;19:21-8.
13. Krag D, Weaver D, Ashikaga T, Moffat F, Klimberg VS, Shriver C, *et al.* **The sentinel node in breast cancer: A multicenter validation study.** *NEJM* 1998; 339(14): 941-946.
14. Chu KU, Roderick R, Turner MD *et al.* **Sentinel node metastasis in patients with breast carcinoma accurately predicts immunohistochemically detectable non sentinel node metastasis.** *Ann Surg Oncol* 1999; 6(8):756-761.
15. Zervos EE, Saha S, Hoshaw-Woodard S, Wheatley GH, Burak WE. **Localising the sentinel node outside of the specialty center: Success of a lymphatic mapping course in disseminating new technology.** *Ann Surg Oncol* 2001; 8(1): 7-12.
16. McIntosh SA, Purushotham AD. **Lymphatic mapping and sentinel node biopsy in breast cancer.** *Br J Surg* 1998; 85: 1347-1356.
17. Haider HR, Khalid T, Ahmed N, Shah SA, Rasheed R, Fatima S, *et al.* **Sentinel node localization in breast carcinoma.** *JCPSP* 2005; Vol 15(4): 215-17.
18. Leong SPL, Donegan E, Heffernon W, Dean S, Katz JA. **Adverse reactions to isosulphan blue during selective sentinel lymph node dissection in melanoma.** *Ann Surg Oncol* 2000; 7(5): 361-366.
19. Giuliano AE. See one, Do twenty Five, Teach One: **The Implementation of Sentinel Node Dissection in Breast Cancer [Editorial].** *Ann Surg Oncol* 1999; 6(6):520-521.
20. Cox CE, Salud CJ, Cantor A, Bass SS, Peltz ES, Ebert MD, *et al.* **Learning curves for breast cancer sentinel lymph node mapping based on surgical volume analysis.** *J Am Coll Surg* 2001c; 193(6): 593-600.
21. Sugg SL, Ferguson DJ, Posner MC, Heimann R. **Should internal mammary nodes be sampled in the sentinel node era?** *Ann Surg Oncol* 2000; 7(3): 188-192.
22. Cox CE. **Lymphatic mapping in breast cancer: Combination technique.** *Ann Surg Oncol* 2001; 8(9S):67-70.
23. Kanwal S, Hussain R. **Sentinel lymph node biopsy in early carcinoma breast with blue dye.** *J Coll Physicians Surg Pak* 2005;15(8):515-6.